



A 17-Year-Old Male with Blurred Vision in the Left Eye

Abdallah M. Jeroudi, MD; Daniel P. Joseph, MD, PhD



Introduction:

A 17-year-old male presented for evaluation for fluctuating vision loss and blurring in the left eye of several month's duration that primarily affected the center of his vision.

He was born full-term through an uncomplicated pregnancy and was otherwise healthy. He denies medication use, supplementation use, and tobacco / alcohol / drug use. He denied antecedent trauma to the eye, recent travel, or recent illness.

The family denied a history of unexplained vision loss, retinal disease, glaucoma, or blindness in the family. He was referred by his primary eye care specialist for inability to improve visual acuity with refraction, significant symptoms of blurring, and for findings detected on dilated fundus examination of the left eye.

Visual acuity measured 20/20 OD and 20/25 OS. There was no relative afferent pupillary defect. The intraocular pressure, extraocular motility, and the anterior segment examination were normal in both eyes.

Dilated fundus examination of the right eye revealed a cup to disc ratio of 0.4 with normal coloration and appearance, clear media, and normal macula, vessels, and periphery. In contrast, the dilated fundus examination of the left eye revealed an enlarged cup to disc ratio with a grey-white oval appearing depression in the temporal optic nerve head (Figure 1 A&B). There were subtle pigmentary changes in the macula with loss of the normal foveal light reflex. The remainder of the extended ophthalmoscopy in the left eye was normal.

Spectral Domain Optical Coherence Tomography (SD-OCT) showed a compact fovea with a normal appearance to the retinal layers of the right eye. SD-OCT of the left eye exhibited cystoid changes involving the outer

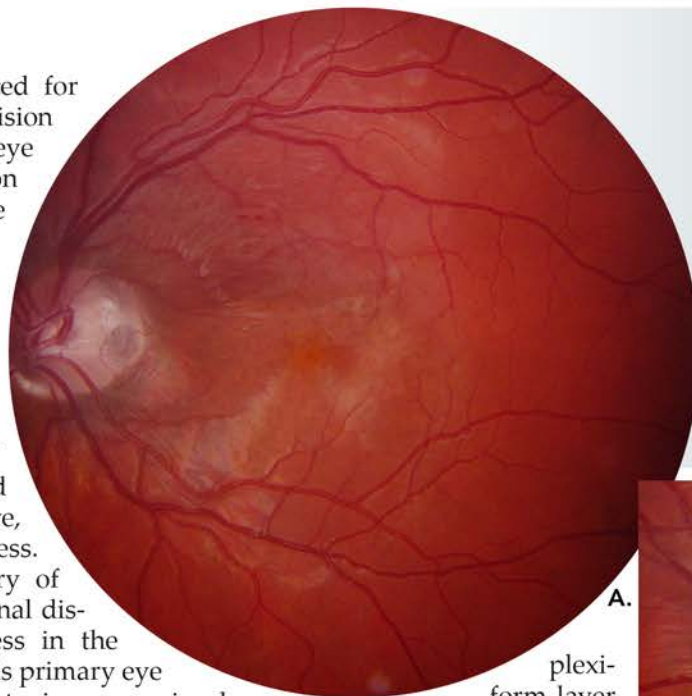
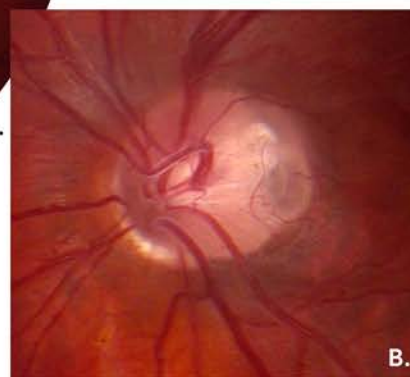

Figure 1 – A. (Left) Color photograph of the left eye showing the grey-white oval depression in the temporal optic nerve head and subtle macular changes.

B. (Below) Enlarged to enhance detail of the finding.



plexiform layer of the central macula with subretinal fluid and irregularity of the underlying retinal pigment epithelium (RPE) signal (Figure 2). The temporal optic nerve head had an excavated appearance as well.

Work Up and Course:

Considering the patient's age and the clinical appearance of the optic nerve head with the macular findings detected by examination and OCT, the findings were consistent with an Optic Disc Pit with development of Optic Disc Pit Maculopathy.

After discussing with the patient and his family, they opted for conservative management with initial observation. After a 6-week and 4-month visit (Figure 3), the vision deteriorated to 20/40 OS with the patient experiencing significant symptomatic blurring on the 4-month visit. Of note on OCT there was a significant increase of the intraretinal fluid now involving the inner plexiform layer and nerve fiber layer. The patient and his family

opted for surgical management consisting of pars plana vitrectomy, internal limiting membrane (ILM) peeling, juxtapapillary laser application, and gas endotamponade with 1 week of face down positioning. The surgery and its post-operative course were well tolerated and review of the patient's OCT scans in the 20-months following surgery showed steady improvement to resolution of the cystoid changes and recovery of the vision to 20/20 OS with resolution in his symptoms of blurring (Figure 4 A-G). The fluid accumulation in the inner plexiform layer was the first to resolve and corresponded to significant improvement of the patient's symptoms and his visual acuity.

Discussion:

Optic Disc Pits (ODP) are a rare, congenital optic disc anomaly characterized by a cavitory appearance to the optic nerve head typically located in a temporal or inferotemporal location. ODPs are estimated to occur in 1 of 11,000 eyes with equal prevalence in males and females [1,2]. They are typically unilateral though 10 to 15% of cases may be bilateral. They are mainly located temporally (70%), centrally (20%), and less often inferiorly / superiorly / nasally (10%) [1,2]. ODPs are oval in shape and have a coloration that may be grey-white (60%), white-yellow (30%), or black (10%) with a size of 0.1 to 0.7 disc diameters. Occasionally, a cilioretinal vessel may be seen emanating from the ODP [1]. Histologically, ODPs appear as a herniation of dysplastic retina into an excavated space in the lamina cribrosa of the optic nerve head leading to a communication with the subarachnoid space [2]. In contradistinction to a chorioretinal coloboma involving the optic nerve head (a failure of closure of the embryonic fissure), ODPs do not disrupt the disc margin.

ODPs are typically identified incidentally on examination. In isolation (from an ophthalmic perspective), ODPs have been associated with detected visual field defects such as enlargement of the physiologic blind spot and a cecocentral scotoma [2]. Yet as part of the category of congenital optic disc anomalies, the presence of ODPs may have important systemic associations in the pediatric patient including basal encephalocele, Aicardi Syndrome, Alagille Syndrome, and bilateral renal hypoplasia [1,2].

ODPs may lead to progressive vision loss in an estimated 25 to 75% of eyes with the development of Optic Disc Pit Maculopathy characterized by the development of

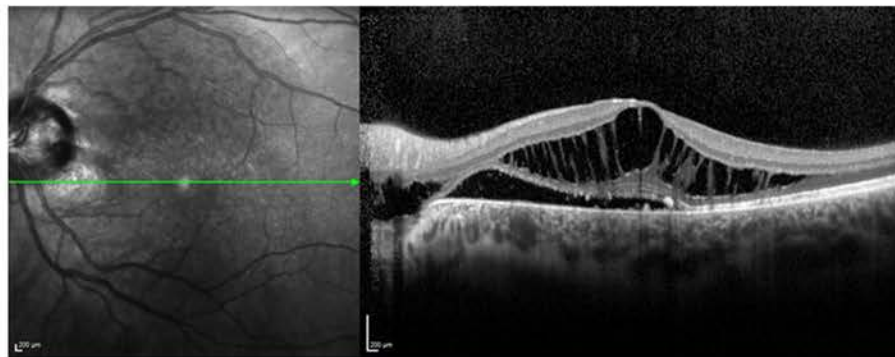


Figure 2 – SD-OCT of the left eye at initial presentation, the vision was 20/25.

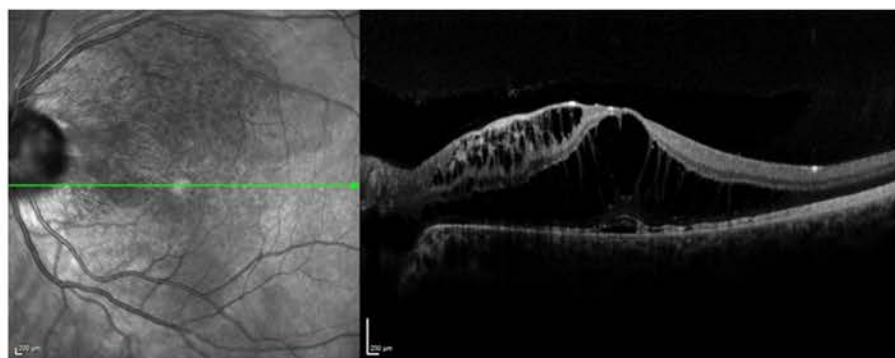


Figure 3 – SD-OCT of the left eye 4 months after initial presentation showing interval worsening, the vision was 20/40 with significant worsening of blurring symptoms.

subretinal fluid accumulation, intraretinal fluid, and RPE changes [2,3]. It typically occurs in patients in the third and fourth decades of life, but may be seen earlier and later in life [2]. Although approximately 25% of cases may self-resolve, 80% of patients with persistent / worsening maculopathy attain VA of 20/200 or worse which prompts management of this condition [2,4]. It is unclear where the fluid originates from and why the maculopathy occurs later in life in this congenital optic disc anomaly, but there are several hypotheses for the source of this fluid of which there is no consensus.

The first hypothesis is that the source of the fluid is from the vitreous. It was thought that the development of a posterior vitreous detachment (PVD) may lead to the onset of the maculopathy, but this would not explain maculopathy in pediatric patients with formed, attached vitreous. Studies using India ink dye injected in the vitreous cavity of dogs with ODPs did show promise in detecting the presence of the dye in the subretinal space, but importantly no glycosaminoglycans from the vitreous were found in the subretinal space arguing against the vitreous as the source of the fluid. Some reports of gas and silicone oil endotamponade migrating subretinally in the setting of ODPs have led some to believe that retinal thinning leading to hole formation overlying the optic disc pit allows fluid from the vitreous to accumulate causing the maculopathy, but this has not been proved histologically [2,3].

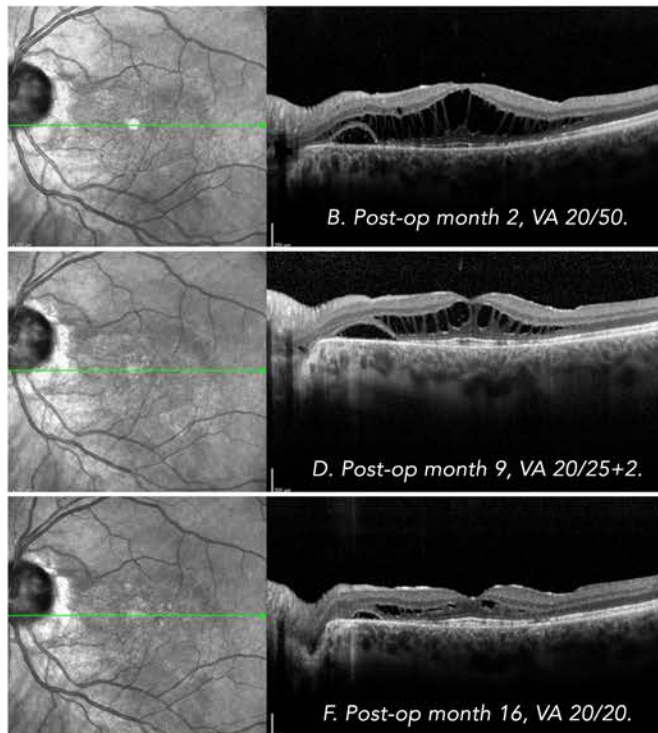
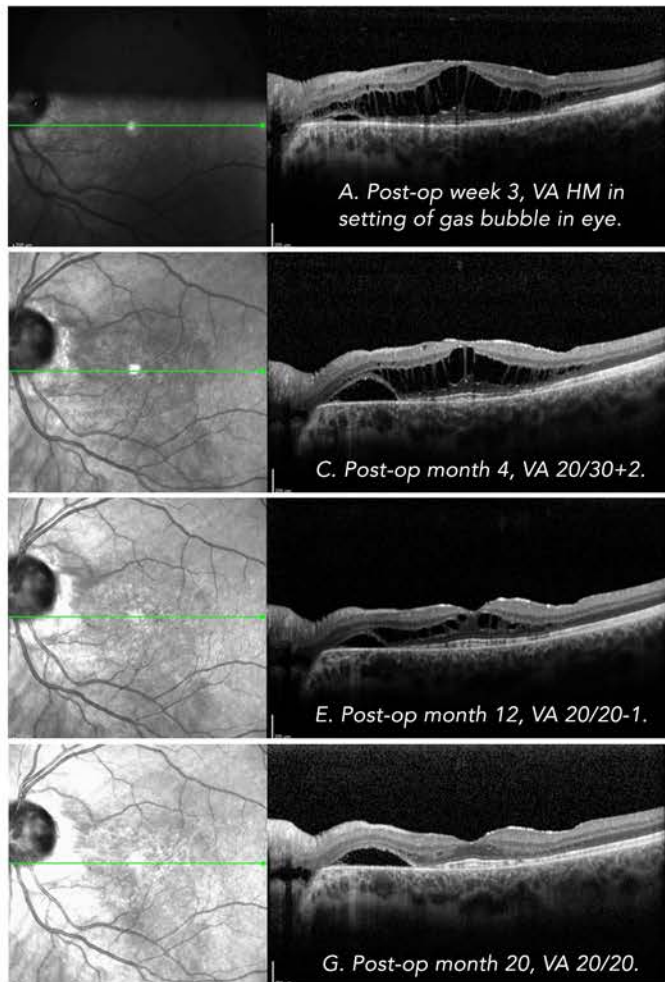


Figure 4 – Serial SD-OCT of the left eye post-operatively showing gradual improvement in the appearance of the schisis-like cystoid spaces and the subretinal fluid. The vision continued to improve at each follow-up visit.

The second hypothesis is that the source of the fluid is from the cerebrospinal space entering through the ODPs. OCT imaging has shown connections between the subretinal and subarachnoid space in the setting of ODPs. One report of intracranial silicone oil migration following retinal detachment repair in a patient with ODP have argued for the connection between the subarachnoid and subretinal space [2,3,5].

The third hypothesis is that the source of the fluid is from blood vessels located at the ODP. Fluorescein angiography showing late hyperfluorescence at the ODP has been used to argue for the hypothesis, but this finding has not been demonstrated reliably in all patients with ODP maculopathy [2,3].

The fourth hypothesis is that the source of the fluid is from the choroid through atrophy of Bruch's membrane at the edge of the ODP. This hypothesis is the least likely since subretinal fluid accumulation is not seen in other conditions with significant peripapillary atrophy [2,3].

The sequence of fluid accumulation that leads to optic disc maculopathy is thought to begin with the development of the cystoid spaces of intraretinal fluid observed in the outer retinal layers. The presence of this intraretinal fluid then leads to the accumulation of fluid in the subretinal space. In an OCT imaging study of patients

with ODP maculopathy, the fluid seemed to accumulate in the outer retinal layers first followed by involvement of inner retinal layers then the subretinal space (or potentially bi-directional accumulation into these two spaces) [6]. In our patient, the fluid seemed to resolve first in the inner retinal layers then much more slowly in the outer retinal layers which supports this hypothesis of fluid accumulation / burden first involving the outer retinal layers [6]. Interestingly, our patient's worsened symptoms of vision loss and distortion coincided with the development of IPL and NFL cystoid fluid (Figure 3) and improved with resolution of fluid in these layers. Further study in higher definition OCT parameters that correlate with visual morbidity in ODP maculopathy may assist in identifying patients that would benefit from timely intervention as compared to observation. If the fluid does not reach the fovea the patient may be asymptomatic but if the subretinal fluid accumulation leads to foveal detachment, permanent visual deterioration to the level of 20/200 or worse may ensue [2,4-6].

Regardless of which hypotheses of fluid accumulation is correct, the successful management of Optic Pit maculopathy depends on altering the fluid dynamics enough to allow for the timely resorption of macular subretinal fluid and intraretinal fluid prior to death of nerve cells. There are reports of successful management of OPM with observation, photocoagulation, steroids, and gas tamponade with or without

vitrectomy. There is no established consensus on the optimal treatment for ODP maculopathy. Although medical management with oral steroids have been tried in the past, resorbed fluid tended to recur with discontinuation of therapy [3]. Juxtapapillary laser application without vitrectomy just temporal to the disc margin attempts to create a chorioretinal adhesion between the ODP and the subretinal space and has had some success in the literature, but time to resolution can be long and laser application can cause significant visual field loss. Intravitreal gas injection without vitrectomy has had < 50% success in the literature, but when paired with juxtapapillary laser had 75% success in fluid resolution in one small series [3]. Most series of ODP maculopathy have been managed using pars plana vitrectomy leading to induction of a complete PVD with or without juxtapapillary endolaser and gas endotamponade [3,5,7]. In these small series, VA improved significantly in 57% to 100% of patients and fluid resolved in 50 to 100% of patients [3]. In these series, the authors all agree on the core principles of PVD induction and gas endotamponade for successful surgery [3,5]. The addition of juxtapapillary laser to create chorioretinal scarring at the edge of the ODP may or may not be required for resolution of fluid [7]. But those who do think chorioretinal adhesion at the peripapillary margin is important need be wary of the damage the laser can cause to the maculopapular (MP) bundle. To minimize risk to the MP bundle, it is recommended that laser burns be carefully titrated from power settings used to create retinopexy adhesions. It is also recommended that laser not be done while there is subretinal fluid in the area of treatment since the increased energy required to obtain photocoagulation burns risks thermal injury to the adjacent tissues. The role of adjunctive steps such as submacular drainage of fluid or internal limiting membrane (ILM) peeling is not clear, but ILM peeling has been thought by some authors to increase success rates of fluid resolution in patients with ODP maculopathy exhibiting multi-layered macular schisis [3]. Newer surgical techniques to physically “occlude” the ODP using autologous platelets, inverted ILM flaps, fibrin sealant, and harvested autologous sclera have also been described with success in some case reports and series [3].

In terms of improvement following surgical management, the time to resolution of the intraretinal and subretinal fluid can be lengthy with one large multi-center series reporting a mean time to resolution of 12.1 ± 10.6 months [7].

Conclusions:

Optic Disc Pits are a rare, congenital optic disc anomaly that may occur in 1 of 11,000 eyes with equal prevalence in males and females. Most cases are unilateral with 10 to 15% of cases presenting bilaterally. They are

typically located temporally (70%) and centrally (20%) with a grey-white or white-yellow appearance. ODPs are identified on routine examination and, in isolation, may lead to a finding of enlarged blind spot or cecocentral scotoma. In a pediatric population, there are syndromic considerations to keep in mind as with many of the congenital optic disc anomalies.

The development of Optic Disc Pit Maculopathy can lead to visual morbidity with 80% of patients with untreated, persistent fluid involving the fovea attaining VA worse than 20/200. Not every patient with Optic Disc Pits will develop maculopathy. ODP maculopathy tends to occur in patients when they reach the third and fourth decades of life, but it may occur sooner in life as demonstrated by our present case. Consensus regarding the source of the fluid which causes optic pit maculopathy is lacking but most specialists would agree that the fluid either arises from vitreous cavity or the subarachnoid space or possibly both.

The management of optic pit maculopathy causing vision loss centers around the timing of surgical management and seeks to address these two hypothesis of fluid sources by induction of a PVD, application of juxtapapillary laser to create a chorioretinal scar barrier between the ODP and the subretinal space, and gas endotamponade to prevent fluid migration through the ODP. Recent studies suggest occlusion of the ODP with either ILM, autologous platelets/tissue, or fibrin sealant may also be beneficial [3,5]. The fluid resolution following surgery can take a significant amount of time on the order of several months to nearly 2 years.

References:

1. Georgalas I, Ladas I, Goergopoulos G, Petrou P. “Optic disc pit: a review.” *Graefes Arch Clin Exp Ophthalmol*. 2011; 249(8):1113-22.
2. Sadun A, Khaderi K. “Chapter 93: Optic Disc Anomalies, Pits, and Associated Serous Macular Detachment.” In: Ryan SJ, Schachar AP eds. *Retina* 5th ed. Elsevier Saunders.
3. Moisseiev E, Moisseiev J, Loewenstein A. “Optic disc pit maculopathy: when and how to treat? A review of the pathogenesis and treatment options.” *Int J Retina Vitreous*. 2015; 7:1:13.
4. Sobol WM, Blodi CF, Folk JC, Weingeist TA. “Long-term visual outcome in patients with optic nerve pit and serous retinal detachment of the macula.” *Ophthalmology*. 1990; 97(11):1539
5. Jain N, Johnson MW. “Pathogenesis and treatment of maculopathy associated with cavitory optic disc anomalies.” *Am J Ophthalmol*. 2014; 158(3):432-35.
6. Roy R, Waanbah AD, Mathur G, Raman R, et al. “Optical coherence tomography characteristics in eyes with optic pit maculopathy.” *Retina*. 2013;33:771-75.
7. Abouammoh MA, Alsulaiman SM, Gupta VS, Mousa A, et al. “Pars plana vitrectomy with juxtapapillary laser photocoagulation versus vitrectomy without juxtapapillary laser photocoagulation for the treatment of optic disc pit maculopathy: the results of the KKESH International Collaborative Retina Study Group.” *Br J Ophthalmol*. 2016; 100(4):478-83.

