



A 30-Year-Old Woman with Blurry Vision and “Dark Splotches”

Yicheng Chen, MD; Daniel P. Joseph, MD, PhD



Introduction:

The patient is a 30-year-old woman with a past medical history of hypertension and myopia. She presents with a 3 day history of blurry vision in the right eye. 1 day prior to presentation, she noticed “dark splotches” in her vision. She denies any recent viral symptoms.

Exam:

On exam her visual acuity was 20/60 in the right eye and 20/25 in the left eye with correction. Confrontational visual fields were full. Her anterior chamber exam was within normal limits in both eyes. Fundus exam of the right eye revealed blurring of the optic disc margins in the right eye as well as multiple flat grey-white lesions in the posterior pole outside of the macula as well as the mid-periphery. There was a yellow granularity to the fovea in the right eye. The fundus exam of the left eye was within normal limits (Figure 1).

Fluorescein angiogram showed punctate areas of hyperfluorescence with late staining in the posterior pole and mid-periphery corresponding to the grey-white lesions on color photography. In addition, there was staining of the right optic nerve head (Figure 2). The fluorescein angiogram of the left eye was normal.

Optical coherence tomography of the right macula demonstrated localized disruptions in the ellipsoid zone. OCT of the left macula was normal (Figure 3).

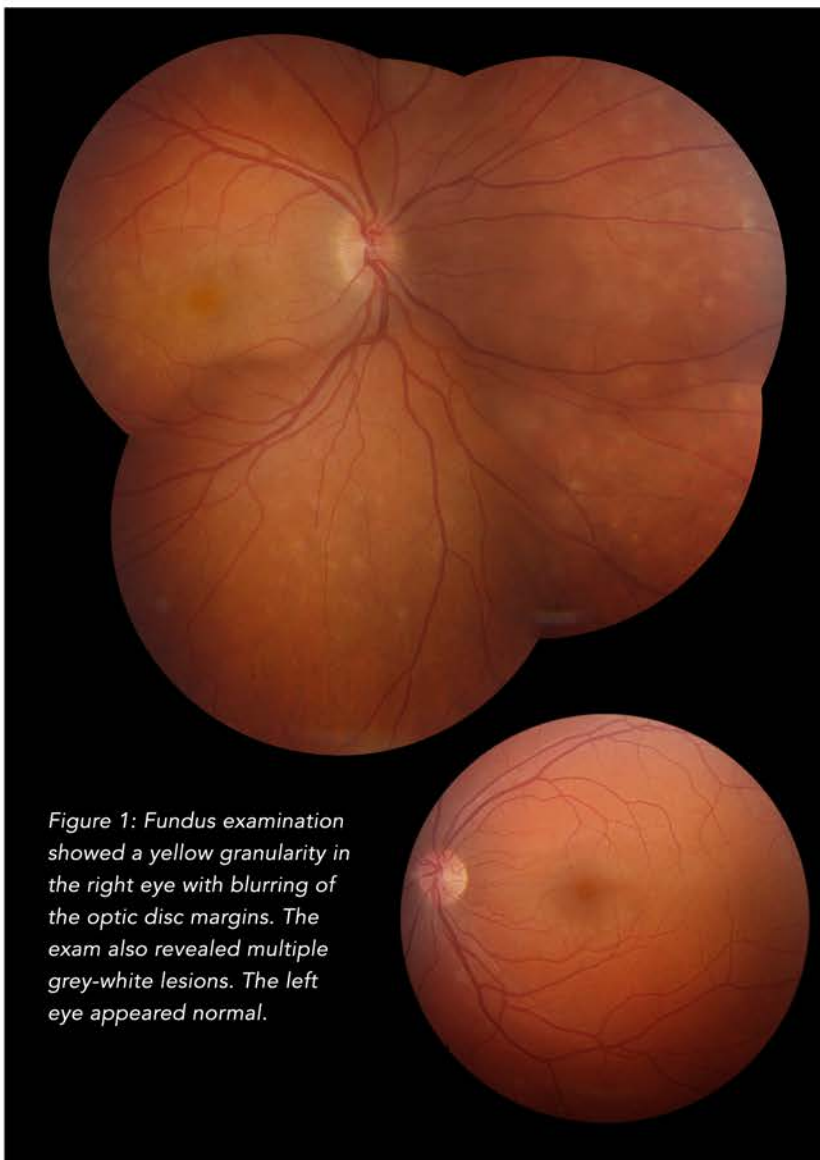


Figure 1: Fundus examination showed a yellow granularity in the right eye with blurring of the optic disc margins. The exam also revealed multiple grey-white lesions. The left eye appeared normal.

Discussion:

The patient's age, medical history, exam findings and imaging support the diagnosis of multiple evanescent white dot syndrome (MEWDS). MEWDS is a syndrome first described by Lee Jampol et al. in 1984 [1]. Initially described as a unilateral condition occurring predominantly in young female patients (75% female) with a mean age of

28 years, MEWDS is characterized by small white lesions localized to the peri-foveal area and mid-periphery and is almost always unilateral. Macular granularity of the affected eye is another characteristic finding in MEWDS. Disc edema, photopsias, enlarged blind spot and posterior vitreous cells may also be present [1,2]. An association with myopia and a "flu-like" prodrome has been described [3,4].

On fluorescein angiogram, there is early hyperfluorescence with late staining of the lesions [1,2,5]. The angiographic lesions have been classified as dots (~100 microns), often in a wreathlike pattern as well as larger spots (>200 microns) which are located more posteriorly. On ICG angiography late phase hypocyanescent areas can be seen that correspond to the hyperfluorescent lesions on FA [6]. On OCT, subtle disruptions of the ellipsoid zone have been described [7].

The pathogenesis of MEWDS is still unknown, but it has been theorized that an autoimmune-mediated inflammatory process is responsible [2]. Patients usually experience almost total recovery without intervention, with a mean interval of 7-10 weeks [1,5].

Summary:

Our patient is a young myopic female who displays many of the features associated with MEWDS, including unilateral white dot lesions in the posterior pole and

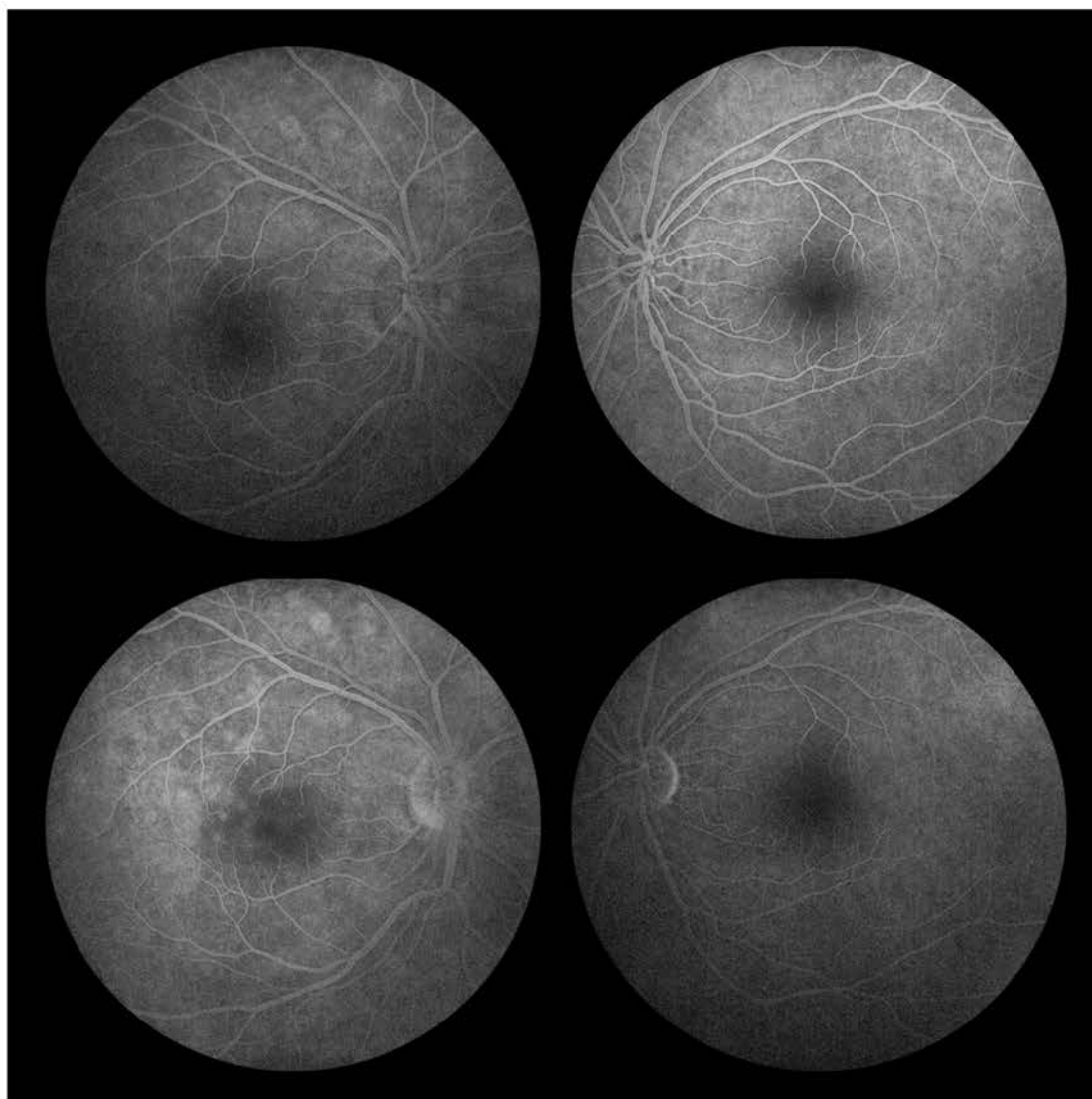


Figure 2: The FA showed areas of hyperfluorescence that correspond to the grey-white lesions on color photos. There is also staining of the optic nerve head in the right eye. The left eye was normal.

mid-periphery. She also has the classic foveal granularity in the right eye compared to the normal left eye. The hyperfluorescent lesions on the FA and the ellipsoid zone disruption on the OCT are also consistent with a diagnosis of multiple evanescent white dot syndrome.

At her 2 week follow-up visit, the patient's vision improved to 20/30 in the right eye. The grey-white lesions on fundus exam had resolved, but the granularity of the fovea was still evident. The ellipsoid zone disruptions on OCT were resolving as well. The left eye remained normal.

References:

1. Jampol LM, Sieving PA, Pugh D, Fishman GA, Gilbert H. Multiple evanescent white dot syndrome. I. Clinical findings. Arch Ophthalmol. 1984 May;102(5):671-4.

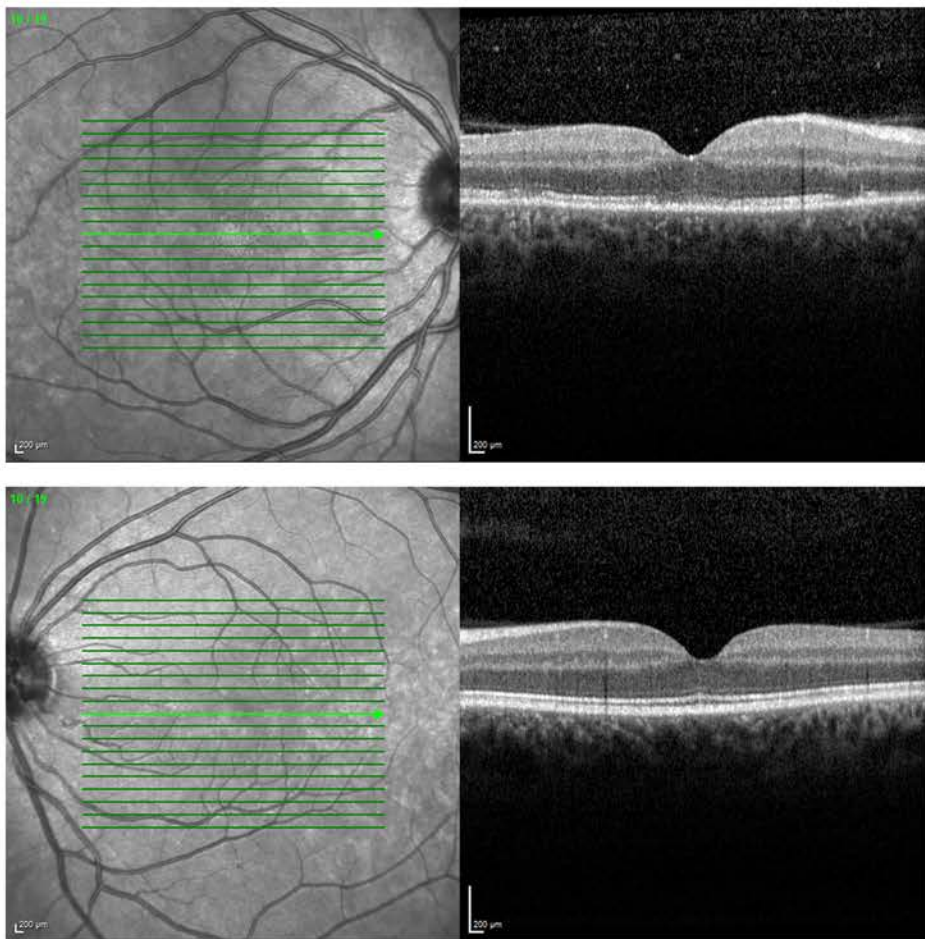


Figure 3: OCT of the right macula showed localized disruptions in the ellipsoid zone. The left macula was normal.

2. Jampol LM, Becker KG. White spot syndromes of the retina: a hypothesis based on the common genetic hypothesis of autoimmune/inflammatory disease. *Am J Ophthalmol.* 2003 Mar;135(3):376-9.

3. Asano T, Kondo M, Kondo N, Ueno S, Terasaki H, Miyake Y. High prevalence of myopia in Japanese patients with multiple evanescent white dot syndrome. *Jpn J Ophthalmol.* 2004 Sep-Oct;48(5):486-9.

4. Chung YM, Yeh TS, Liu JH. Increased serum IgM and IgG in the multiple evanescent white-dot syndrome. *Am J Ophthalmol.* 1987 Aug 15;104(2):187-8.

5. Marsiglia M, Gallego-Pinazo R, Cunha de Souza E, Munk MR, Yu S, Mrejen S, Cunningham ET Jr, Lujan BJ, Goldberg NR, Albin TA, Gaudric A, Francais C, Rosen RB, Freund KB, Jampol LM, Yannuzzi LA. EXPANDED CLINICAL SPECTRUM OF MULTIPLE EVANESCENT WHITE DOT SYNDROME WITH MULTIMODAL IMAGING. *Retina.* 2016 Jan;36(1):64-74.

6. Gross NE, Yannuzzi LA, Freund KB, et al. Multiple evanescent white dot syndrome. *Arch Ophthalmol* 2006;124:493-500.

7. Nguyen MH, Witkin AJ, Reichel E, et al. Microstructural abnormalities in MEWDS demonstrated by ultrahigh resolution optical coherence tomography. *Retina* 2007;27:414-418.



MAKE YOUR
RESERVATION TODAY!
(Space is limited)

SPRING RETINA UPDATE
May 14, 2016
Drury Inn; 8700 Eager Road
St. Louis, MO 63144

Contact Kelly McKittrick
for more info or to register:
kelly.mckittrick@rc-stl.com
314-367-1181 x-2157



THE RETINA INSTITUTE
(314) 367-1181
tri-stl.com

Kevin J. Blinder, MD
Nicholas E. Engelbrecht, MD
M. Gilbert Grand, MD

Daniel P. Joseph, MD, PhD
Thomas K. Krummenacher, MD
Richard J. Rothman, MD

Gaurav K. Shah, MD
Bradley T. Smith, MD
Matthew A. Thomas, MD