



A 15-Year-Old Female with Vision Loss in the Left Eye

Abdallah Jeroudi, MD; Thomas K. Krummenacher, MD



Introduction:

A 15-year-old female presented for examination after incidental detection of a lesion in the left eye. She did not identify a visual complaint until the date of her examination when monocular vision testing was performed. She was born full-term and was otherwise healthy. She denies medication, tobacco, alcohol, or drug use. The family denied a history of vision loss, retinal disease, glaucoma, or blindness. The patient was referred for decreased vision and for a finding on dilated fundus examination in the left eye.

Visual acuity measured 20/20 OD and 20/80 OS. There was no relative afferent pupillary defect. Extraocular motility, intraocular pressure, and anterior segment examination were normal.

Dilated fundus examination revealed a cup to disc ratio of 0.1 with sharp disc margins. The vitreous was clear. Notable on examination was a large, peripapillary and macular amelanotic choroidal lesion with subretinal hemorrhage located in the nasal macula (Figure 1). Fluorescein angiogram did not confirm a presence of CNVM with blockage noted in the area of hemorrhage. B scan ultrasonography of the lesion showed increased hyperechoicity of the involved area with shadowing consistent with calcification (Figure 2).

Work Up and Course:

Considering the clinical appearance of the lesion coupled with the presence of calcification and the patient's age, the lesion was consistent with a choroidal osteoma.

Although subretinal hemorrhage was detected by examination, fluorescein angiography did not disclose the presence of CNVM so observation was pursued. The patient did not re-present for evaluation until 2 years later for which she was found to have mild

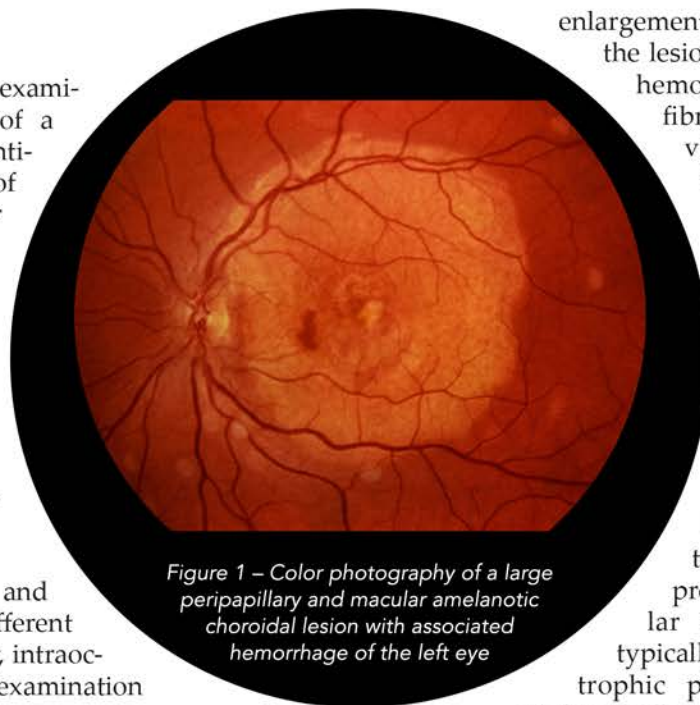


Figure 1 – Color photograph of a large peripapillary and macular amelanotic choroidal lesion with associated hemorrhage of the left eye

enlargement at the margins of the lesion, a small subretinal hemorrhage, central fibrotic changes, and vision loss to the 20/400 level OS (Figure 3).

Discussion:

Choroidal osteoma is a benign intraocular ossifying tumor typically found in otherwise healthy eyes [1,2]. This is in contradistinction to most processes of intraocular calcification which typically occurs as a dystrophic process such as in phthisis bulbi and chronic intraocular inflammation. Choroidal osteoma is characterized by the formation of mature bone which gradually replaces the choroid of the involved area. This sporadic condition has no racial predilection and typically occurs in young females in the second to third decade of life. Although it may present bilaterally, 75% of cases present with unilateral involvement [2]. It is unclear why these lesions occur in these otherwise healthy eyes. Hypotheses including hormonal influences as well as growth of a pre-existing choristoma in the area have been postulated. Choroidal osteoma is quite rare even among robust, tertiary-center ocular oncology practices [1,2].

On examination, choroidal osteomas typically have a yellow-orange coloration with increased pallor and overlying RPE clumping / atrophy over time. The lesion is often round with scalloped margins. Choroidal osteomas usually occur in the peripapillary region with extension of the lesion into the macula [2]. Very rarely do these tumors have a purely macular location, and choroidal osteomas do not occur anterior to the major arcades. Indeed, choroidal osteomas are often mistaken

for idiopathic sclerochoroidal calcifications; a benign calcification which commonly occurs in the elderly as a solitary lesion anterior to the arcades [2,3]. Sometimes the intrinsic vasculature of the choroidal osteoma can be detected by clinical examination which is not to be confused with neovascularization [2].

Although patients may present without symptoms, visual morbidity in the form of vision loss, scotoma, and metamorphopsia may occur. Vision is adversely affected by a combination of RPE / photoreceptor atrophy overlying the lesion (especially when decalcification of the tumor occurs), serous exudation from the lesion, and formation of choroidal neovascular membranes (CNVMs) leading to exudation and subretinal hemorrhage [1,2]. The clinical course may be variable with CNVM reported in 31% of cases by 5 years, up to 47% of cases by 10 years, and up to 56% of cases by 20 years [1]. Vision loss to a level worse than 20/200 was detected in 14% at 1 year, 45% at 5 years, and 56% at 10 years in one large series [1]. Although a tumor, there is no evidence of metastatic disease or increased mortality in patients with choroidal osteoma [2].

The differential diagnosis for choroidal osteoma includes a variety of tumors. The patient history, clinical appearance, and ultrasonography are usually sufficient to determine the presence of choroidal osteoma. Amelanotic melanoma can present with a similar appearance, but choroidal osteomas typically have a well-defined scalloped margin and exhibit increased echogenicity on B-scan ultrasound consistent with calcification [2]. A CT scan of the orbits can also identify a bone signal level of calcification in the area of the lesion (Figure 4). Choroidal metastasis may also present similarly, but typically occur in older patients with a known or suspected history of malignancy. Although posterior scleritis may present with a subretinal white lesion, scleritis would also have associated symptoms and signs such as pain, uveitis, choroidal folds, and thickened sclera. Choroidal hemangioma may also be mistaken for choroidal osteoma, but hemangiomas tend to assume an orange-colored, round, domed appearance with a smooth margin [2].

Treatment has not been well described for this condition, but falls within managing tumor growth, managing tumor calcification, and managing

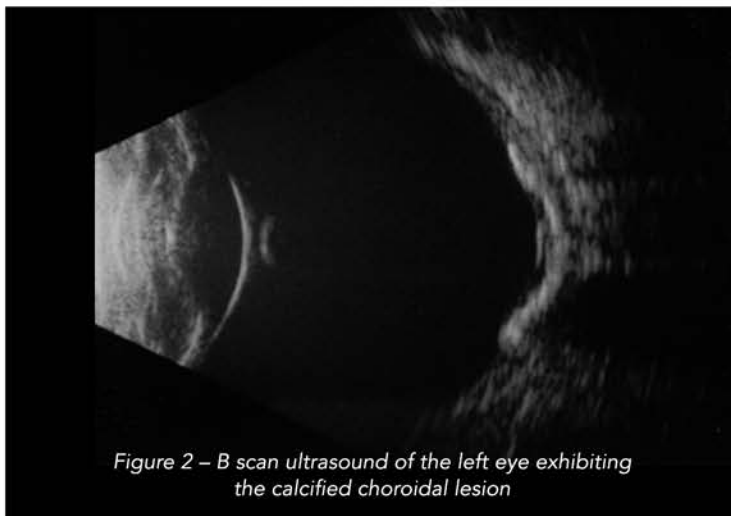


Figure 2 – B scan ultrasound of the left eye exhibiting the calcified choroidal lesion

which has been associated with vision loss due to RPE and photoreceptor atrophy [1,5]. CNVM can be managed using anti-VEGF agents and PDT [6].

Conclusions:

Choroidal osteoma is a benign intraocular ossifying tumor of mature bone which predominantly occurs in otherwise young, healthy females. It presents unilaterally in 75% of cases as an amelanotic (yellow-orange to pale colored), calcified lesion in a peripapillary location involving the posterior pole. Choroidal osteoma does not occur as an isolated, solitary mass anterior to the major arcades. The differential diagnosis of this condition includes amelanotic uveal melanoma, amelanotic nevus, metastasis, choroidal hemangioma, idiopathic sclerochoroidal calcification, and posterior scleritis. The clinical history, clinical examination,

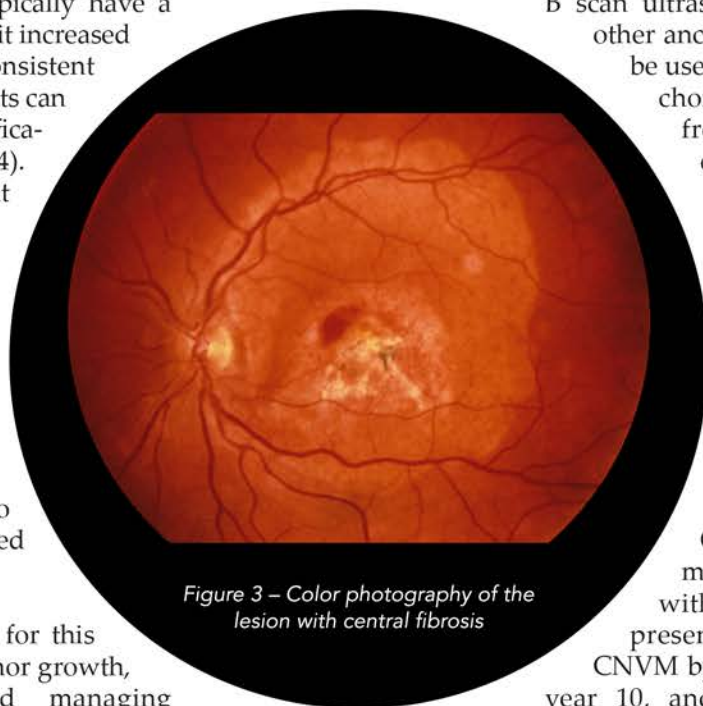


Figure 3 – Color photograph of the lesion with central fibrosis

B scan ultrasonography, and other ancillary testing can be used to differentiate choroidal osteoma from these other conditions. Visual morbidity occurs from exudation / CNVM as well as RPE and photoreceptor atrophy associated with decalcification of the lesion. CNVM is the most concerning with 31% of cases presenting with CNVM by year 5, 47% by year 10, and 56% by year

20. The overall visual prognosis is guarded with 45% of patients by 5 years and 56% of patients by 10 years attaining vision loss worse than 20/200. Treatment is focused to prevent growth of extrafoveal tumors with PDT, prevent decalcification with calcium supplementation in subfoveal tumors, and treating the presence of CNVM with anti-VEGF or PDT. Choroidal osteomas do not metastasize or confer an increased risk of mortality to the patient.

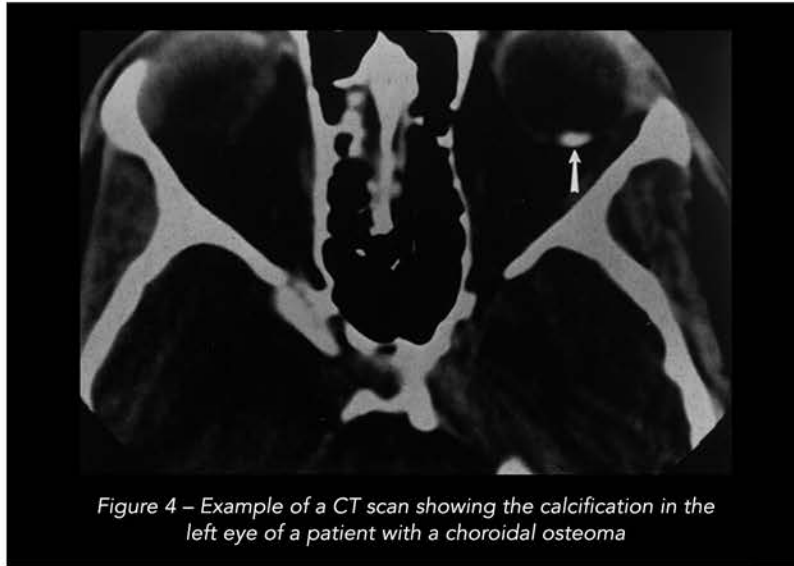


Figure 4 – Example of a CT scan showing the calcification in the left eye of a patient with a choroidal osteoma

References:

1. Shields CL, Sun H, Demirci H, Shields JA. "Factors predictive of tumor growth, tumor decalcification, choroidal neovascularization, and visual outcome in 74 eyes with choroidal osteoma." *Arch Ophthalmol.* 2005;123(12): 1658-66.
2. Shields CL, Brown GC, Sharma S, Shields JA. "Chapter 152: Choroidal Osteoma." In: Ryan SJ, Schachat AP eds. *Retina* 5th ed. Elsevier Saunders.

photodynamic therapy." *Arch Ophthalmol.* 2008; 126(1):135-7.

3. Shields CL, Hasanreisoglu M, Saktanasate J, Shields PW, Seibel I, Shields JA. "Sclerochoroidal calcification: clinical features, outcomes, and relationship with hypercalcemia and parathyroid adenoma in 179 eyes." *Retina.* 2015; 35(3):547-54.
4. Shields CL, Materin MA, Mehta S, Foxman BT, Shields JA. "Regression of extrafoveal choroidal osteoma following photodynamic therapy." *Arch Ophthalmol.* 2008; 126(1):135-7.
5. Shields CL, Perez B, Materin MA, Mehta S, Shields JA. "Optical coherence tomography of choroidal osteoma in 22 cases: evidence for photoreceptor atrophy over the decalcified portion of the tumor." *Ophthalmology.* 2007; 114(12):e53-8.
6. Khan MA, DeCroos FC, Storey PP, Shields JA, Garg SJ, Shields CL. "Outcomes of anti-vascular endothelial growth factor therapy in the management of choroidal neovascularization associated with choroidal osteoma." *Retina.* 2014; 34(9):1750-6.

