



## A 87-Year Old Female with Sudden Vision Loss

Wendy Shieh, MD; Kevin J. Blinder, MD



### Introduction:

An 87-year old female with a medical history significant for hypertension and coronary artery disease complains of sudden, painless vision loss in the right eye 5 weeks prior to presentation. She states that vision in the right eye has gradually improved over time and the left eye is asymptomatic. Pertinent medications include 81-mg aspirin daily, anti-hypertensives, and multivitamins. Previously, she had undergone uncomplicated cataract surgery in both eyes and denies any other ocular history.

### Examination:

On examination, the patient's best-corrected visual acuity (BCVA) was 20/100 in the right eye and 20/40 in the left eye. Pupillary exam did not reveal an afferent pupillary defect and intraocular pressures were within normal limits. Slit-lamp examination showed a normal anterior segment exam with intraocular lenses bilaterally. The posterior pole of the right eye (Figure 1) revealed a mild vitreous hemorrhage as well as retinal hemorrhage in several layers (subretinal, intraretinal and sub-internal limiting membrane (ILM)), with further layering of blood in the pre-retinal plane. OCT of the right macula (Figure 2) showed subretinal hyperreflectivity superiorly while images through the foveal center demonstrated hard exudates and a sub-ILM lucency.

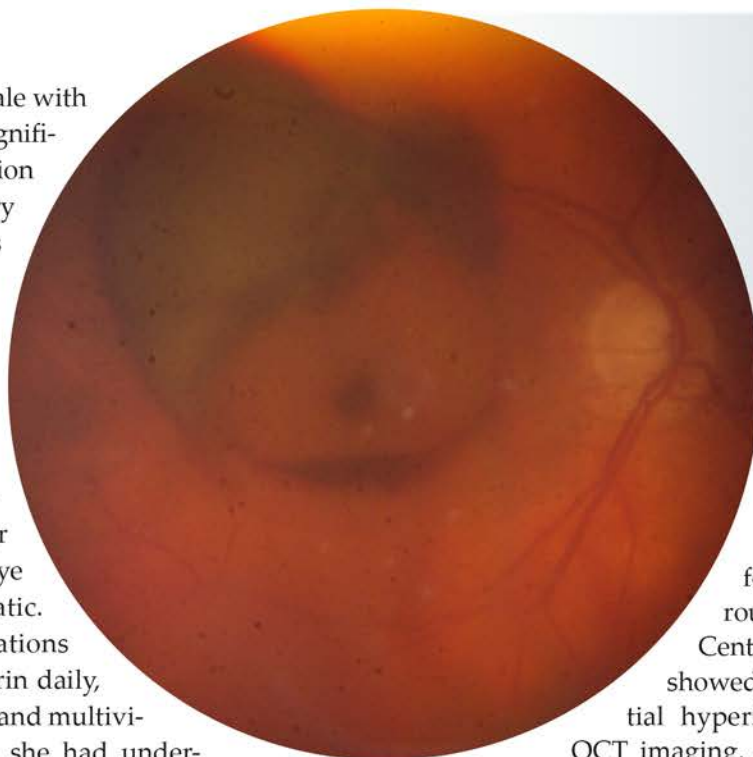


Figure 1. Fundus photograph of the right eye showing mild media opacity from vitreous hemorrhage as well as retinal hemorrhage in several layers (subretinal, intraretinal and sub-internal limiting membrane). There is also layering of blood in the pre-retinal plane.

Fluorescein angiography of the right eye (Figure 3) was most consistent with a retinal artery macroaneurysm (RAM) with a focal hyperfluorescent lesion surrounded by an area of blockage. Centrally, the right eye angiogram also showed an area of pooling below the initial hyperfluorescent spot. Fundus exam, OCT imaging, and angiography of the left eye were unremarkable. Aside from a RAM, the differential diagnosis also included exudative macular degeneration, retinal angiomatous proliferation, and polypoidal choroidal vasculopathy.

Treatment options of observation, laser photocoagulation, and intravitreal anti-VEGF injection were discussed and the patient subsequently received two monthly injections of avastin. At 2-month follow up, the BCVA improved to 20/70 with involution of the RAM lesion. Resolution of subretinal hemorrhage and sub-ILM fluid can also be seen on OCT (Figure 4). Given the lack of further exudation or central edema, the patient will now be conservatively managed with observation.

### Discussion:

Retinal artery macroaneurysms (RAMs) are acquired fusiform or round dilatations of retinal arterioles, commonly found within the first three orders of



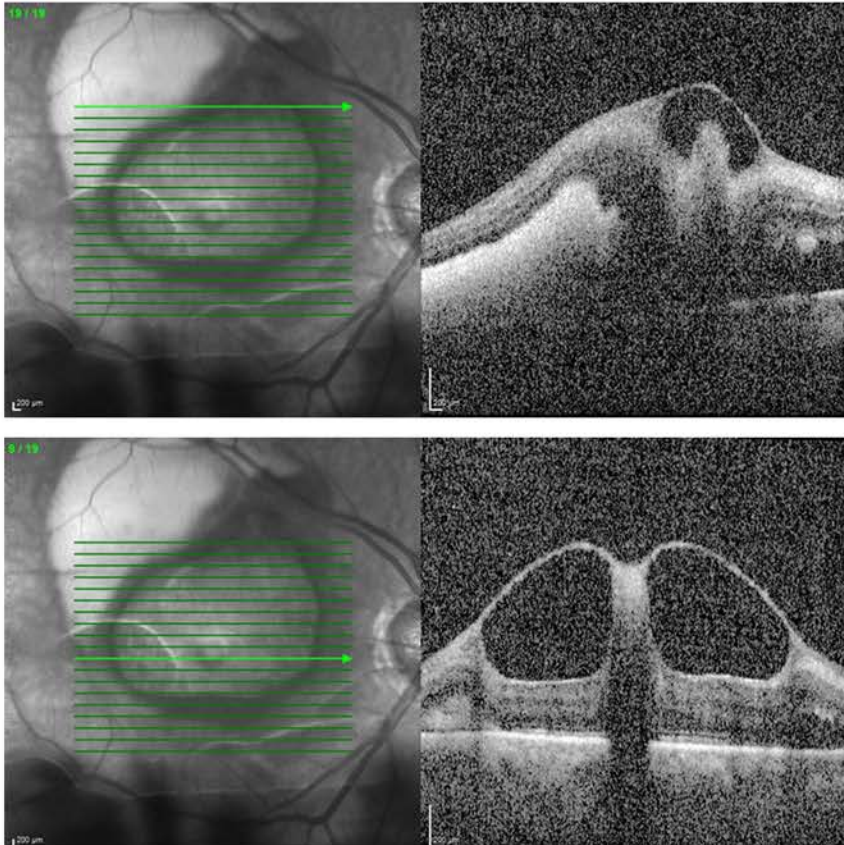


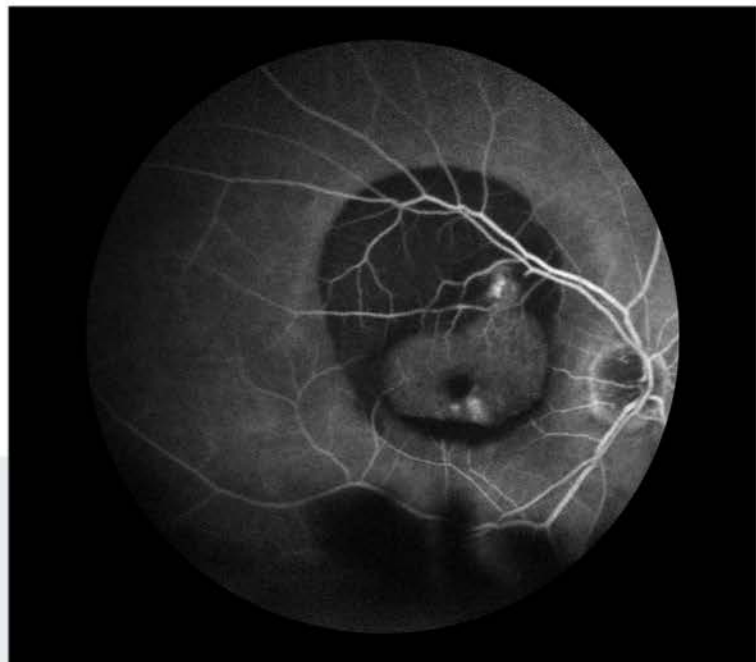Figure 2: OCT of the right macula showing subretinal hyperreflectivity superiorly while images through the foveal center demonstrated hard exudates and a sub-ILM lucency.

bifurcation.<sup>1</sup> Systemic hypertension is the main risk factor for RAMs, followed by female sex and age.<sup>2</sup>

Diagnosis is often made with direct visualization on dilated fundus exam, but fluorescein angiography can be helpful in the setting of multi-layered retinal hemorrhage. OCT imaging may be helpful in surveillance of cases involving macular edema and exudation.

Although majority of RAMs undergo spontaneous involution, associated complications such as macular edema and exudation, end-arteriole occlusion from thrombosis, or hemorrhage due to aneurysm rupture can negatively affect visual outcomes.<sup>2,3</sup>

Figure 3: Fluorescein angiography of the right eye with a focal hyperfluorescent lesion surrounded by an area of blockage. Centrally, late phase images also show an area of pooling below the initial hyperfluorescent spot.



## Treatment:

Various approaches have been described in the management of RAMs. Direct laser photocoagulation can be beneficial for primarily hemorrhagic RAM lesions, but carries the risk of inducing a branch retinal artery occlusion or rupture of the aneurysm.<sup>4,5</sup> Recent studies have also compared focal pulse or subthreshold laser versus threshold laser in the treatment of symptomatic RAMs, suggesting that these modalities can achieve similar outcomes in term of visual acuity and central edema in eyes with an exudative process.<sup>6</sup> Lastly, there is growing literature focused on the role and efficacy of anti-VEGF therapy, especially for lesions located within the arcades or optic disc RAMs.<sup>7-9</sup> Mansour et al. reported a retrospective case series of 32 eyes with symptomatic RAM and treatment with various anti-VEGF agents. Their results showed significant BCVA and central macular thickness improvement at 1, 2, and 3 months after the initial injection, with a mean of 2.7 injections over the follow-up period and no adverse events related to the injections.<sup>10</sup> Our patient's clinical course also supports the potential role of anti-VEGF therapy as an alternative to laser in the management of RAMs.



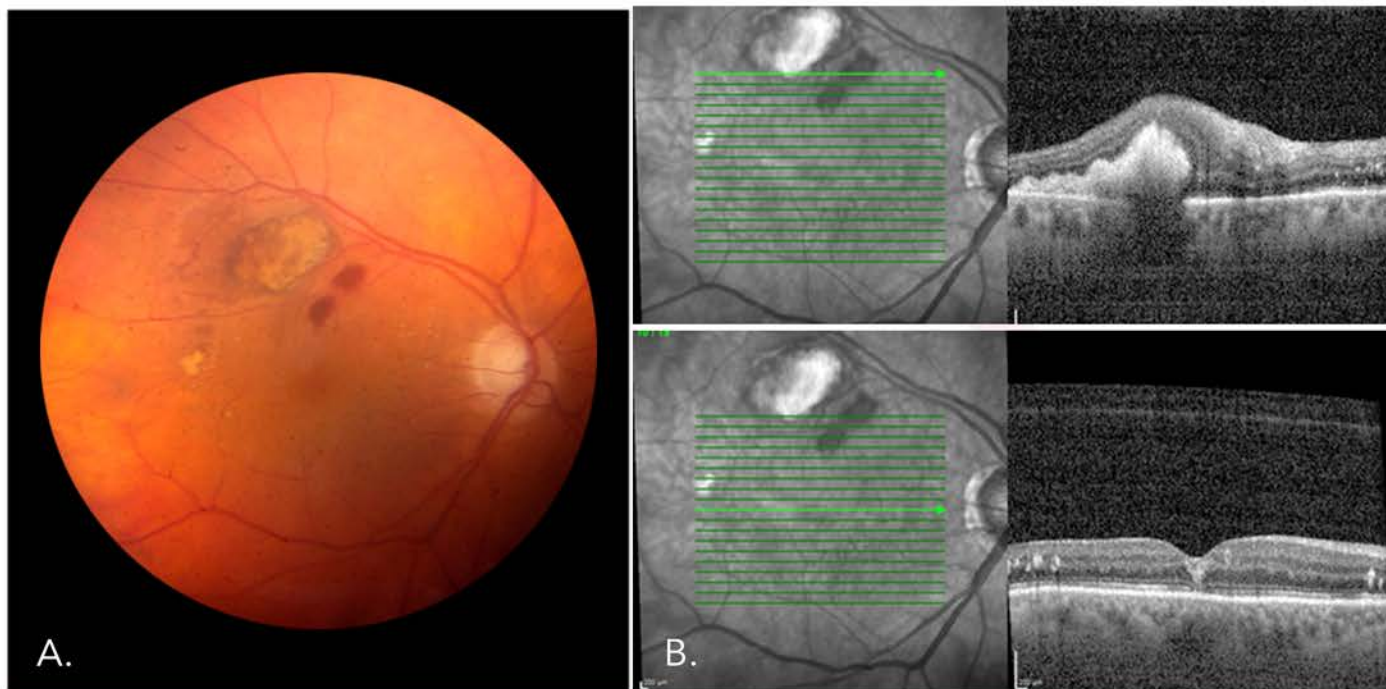


Figure 4: (A) Right eye fundus photo with resolving subretinal and pre-retinal hemorrhage. (B) OCT imaging showing improvement of subretinal hyperreflectivity and sub-ILM fluid.

#### References:

1. Pitkänen L, Tommila P, Kaarniranta K, et al. Retinal arterial macroaneurysms. *Acta Ophthalmol*. 2014 Mar;92(2):101-4.
2. Rabb MF, Gagliano DA, Teske MP. Retinal arterial macroaneurysms. *Surv Ophthalmol* 1988;33:73-96.
3. Panton RW, Goldberg MF, Farber MD. Retinal arterial macroaneurysms: risk factors and natural history. *Br J Ophthalmol* 1990;74:595-600.
4. Meyer JC, Ahmad BU, Blinder KJ, Shah GK. Laser therapy versus observation for symptomatic retinal artery macroaneurysms. *Graefes Arch Clin Exp Ophthalmol* 2015;253:537-541.
5. Russell SR, Folk JC. Branch retinal artery occlusion after dye yellow photocoagulation of an arterial macroaneurysm. *Am J Ophthalmol* 1987;104:186-187.
6. Parodi MB, Iacono P, Ravalico G, Bandello F. Subthreshold laser treatment for retinal arterial macroaneurysm. *Br J Ophthalmol* 2011;95:534-538.
7. Chatziralli I, Maniatea A, Koumbouni K, et al. Intravitreal ranibizumab for retinal arterial macroaneurysm: long-term results of a prospective study. *Eur J Ophthalmol* 2017;27:215-219.
8. Pichi F, Morara M, Torrazza C, et al. Intravitreal bevacizumab for macular complications from retinal arterial macroaneurysms. *Am J Ophthalmol* 2013;155:287-294.
9. Kishore K. Long-term management of complications of retinal artery macroaneurysms with intravitreal aflibercept injection. *Case Rep Ophthalmol* 2016;7:162-171.
10. Mansour AM, Foster RE, Gallego-Pinazo R, et al. Intravitreal anti-vascular endothelial growth factor injections for exudative retinal arterial macroaneurysms. *Retina*. 2018 Mar 2. [Epub ahead of print]

Case of the Month  
Supported by:



Retina Research &  
Development Foundation



THE  
RETINA  
INSTITUTE

1600 S. Brentwood Blvd., Suite 800  
St. Louis, MO 63144

(314) 367-1181  
tri-stl.com

Kevin J. Blinder, MD  
Sabin Dang, MD  
Nicholas E. Engelbrecht, MD  
M. Gilbert Grand, MD  
Daniel P. Joseph, MD, PhD

Thomas K. Krummenacher, MD  
Richard J. Rothman, MD  
Gaurav K. Shah, MD  
Bradley T. Smith, MD  
Matthew A. Thomas, MD